

Parkinson's Disease; A Case Study

History.

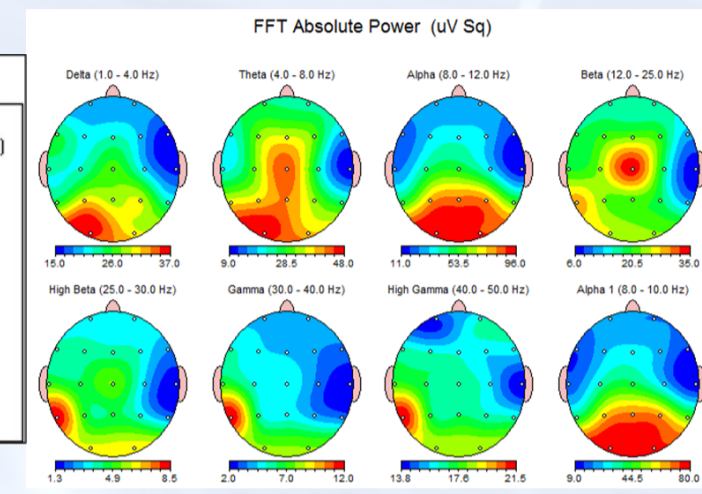
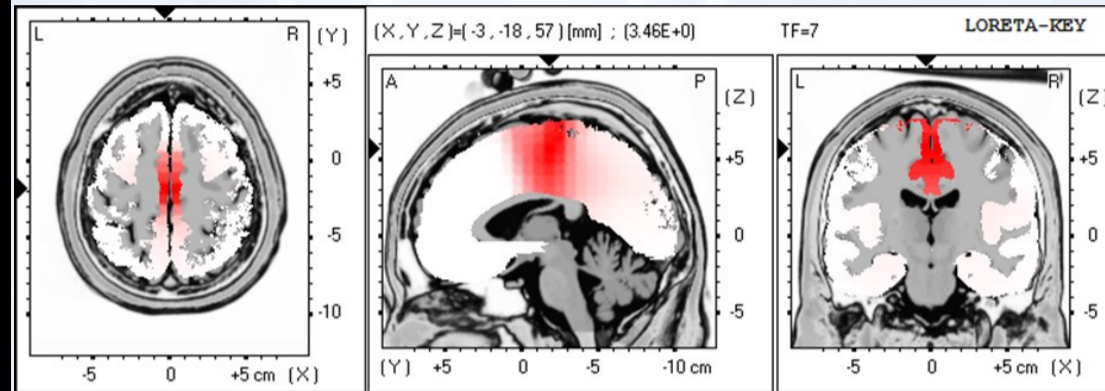
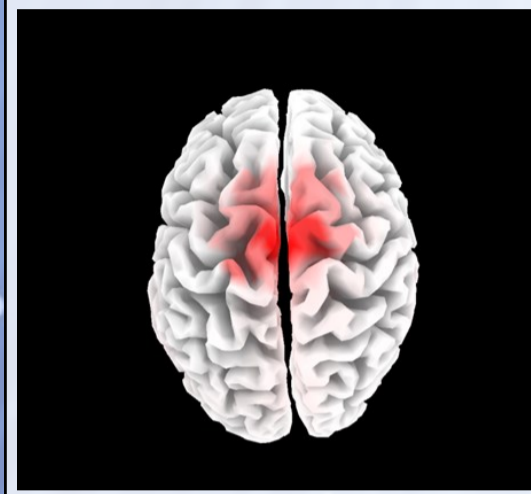
The 64 year old male patient presented with a seven year history of Parkinson's disease and symptoms of bilateral resting tremors, parkinsonian gait, difficulty initiating movement and emotional lability. He had difficulty moving and hence became very introverted stopped socialising and even lacked confidence spending time with his family and grandchildren. He felt like he was a burden to his wife and children and was disappointed that he would not be able to dance at his daughter's upcoming wedding.

Physical Exam

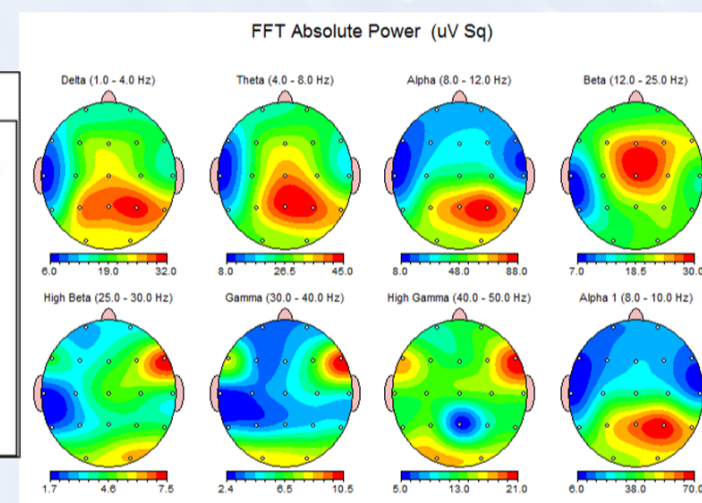
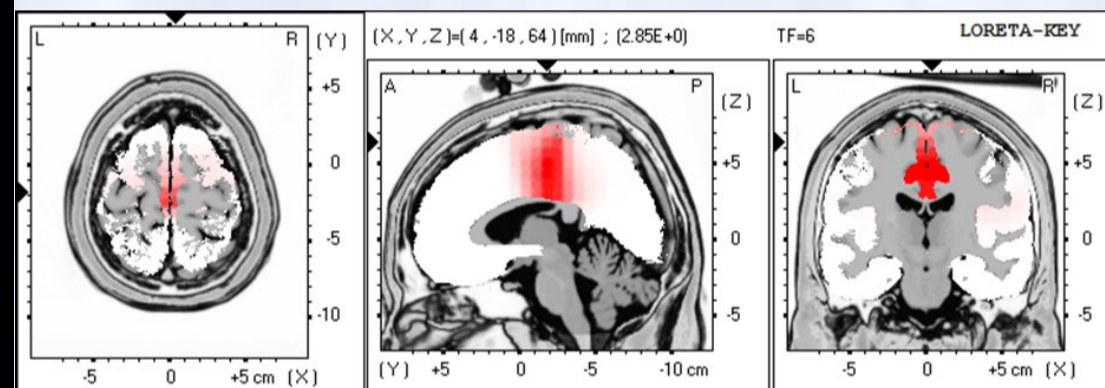
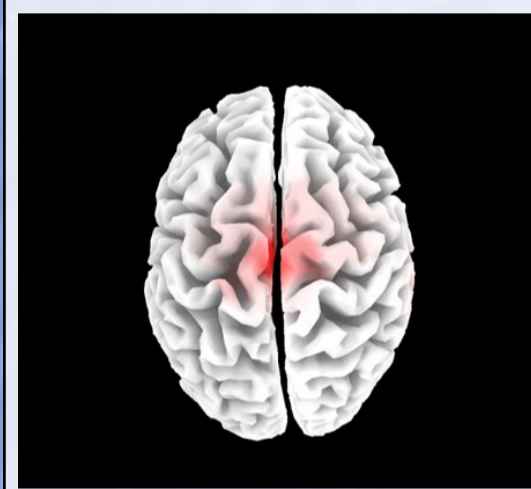
On physical examination the patient's posture was stooped and he had difficulty initiating movement, he demonstrated a shuffling gait and had a resting tremor in his hands bilaterally, worse on the right. The patient had elevated blood pressure bilaterally, optokinetic reflex was dysmetric from right to left and fatigued bilaterally, Romberg's test was positive also causing an increase in his resting tremor. There was a severe intention tremor bilaterally with finger to nose testing, bilateral dysmetria, worse on the left with heel to shin testing and rapid alternating movements at the shoulder and elbow were dysdiadochokinetic with an increased tremor.

The upper and lower limb neurological examination demonstrated an increased tone in the right upper limb and 2-3 beats of clonus in the lower limb; muscle strength was reduced on the left side of the body, vibration sense was reduced in the left lower limb; the left upper body reflexes were increased and the achilles reflex was reduced bilaterally. On cranial nerve examination the pupillary light reflex fatigued immediately, there was right ptosis, bilateral diplopia and left hypertropia, a mild jaw jerk reflex. Webber's test lateralized to the left, left paresis of palatal action was seen and tongue fasciculation was noted.

Initial Findings



Final Findings



Initial Findings:

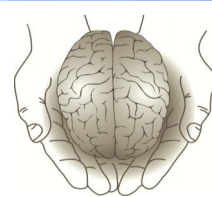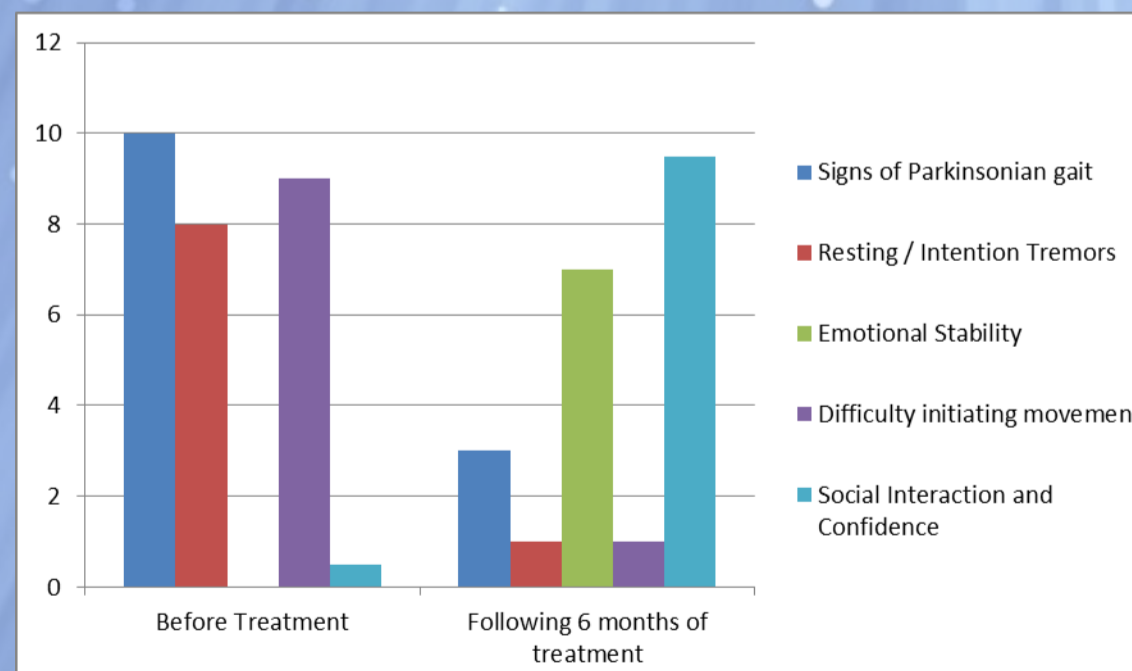
The initial quantitative electroencephalography (QEEG) demonstrated an area of hypoactivity in the right parietal temporal cortex significant in all frequency ranges. Additionally, hyperactivity was seen in the anterior cingulate cortex and left occipital lobe in delta, theta, alpha and beta frequencies. Hypercoherence was found in the frontal cortices bilaterally in the delta frequency and generalised throughout the cortices bilaterally in high beta. Treatment was targeted at normalising activity in the right parietal temporal cortex and in the midline anterior cingulate cortex. Low resolution electromagnetic tomography (LORETA) analysis demonstrates the most significant dysfunction in Brodmann area 6 which is the pre motor cortex and the supplementary motor area. These areas are involved with motor planning and execution.

Report Findings

On follow up assessment at 6 weeks, there was significant normalisation of activity in the right parietal temporal cortex in all frequencies. Coherence activity levels in delta frequency returned almost completely to normal. Brodmann area 38 was now highlighted as having the most significant dysfunction. This is involved with limbic association integration.

Conclusion

After 6 months of treatment, this patient reported life changing improvements. Major symptomatic changes included; a decrease in tremors, increased energy levels and improved dexterity in his right hand. He could not prepare a snack prior to treatment, after a few months of treatment, he assisted in his daughter's restaurant using his hands with precision and contributing meaningfully. He is more active and keeps up with his grandchildren comfortably. He was unable to dance for three years prior to treatment. He now walks long distances daily and does gardening. Most importantly, he proudly announced that he danced at his daughter's wedding! He is more socially confident and feels he can contribute significantly to his family needs.



**Institute of
Functional Neuroscience**
By: IFN Clinical Staff